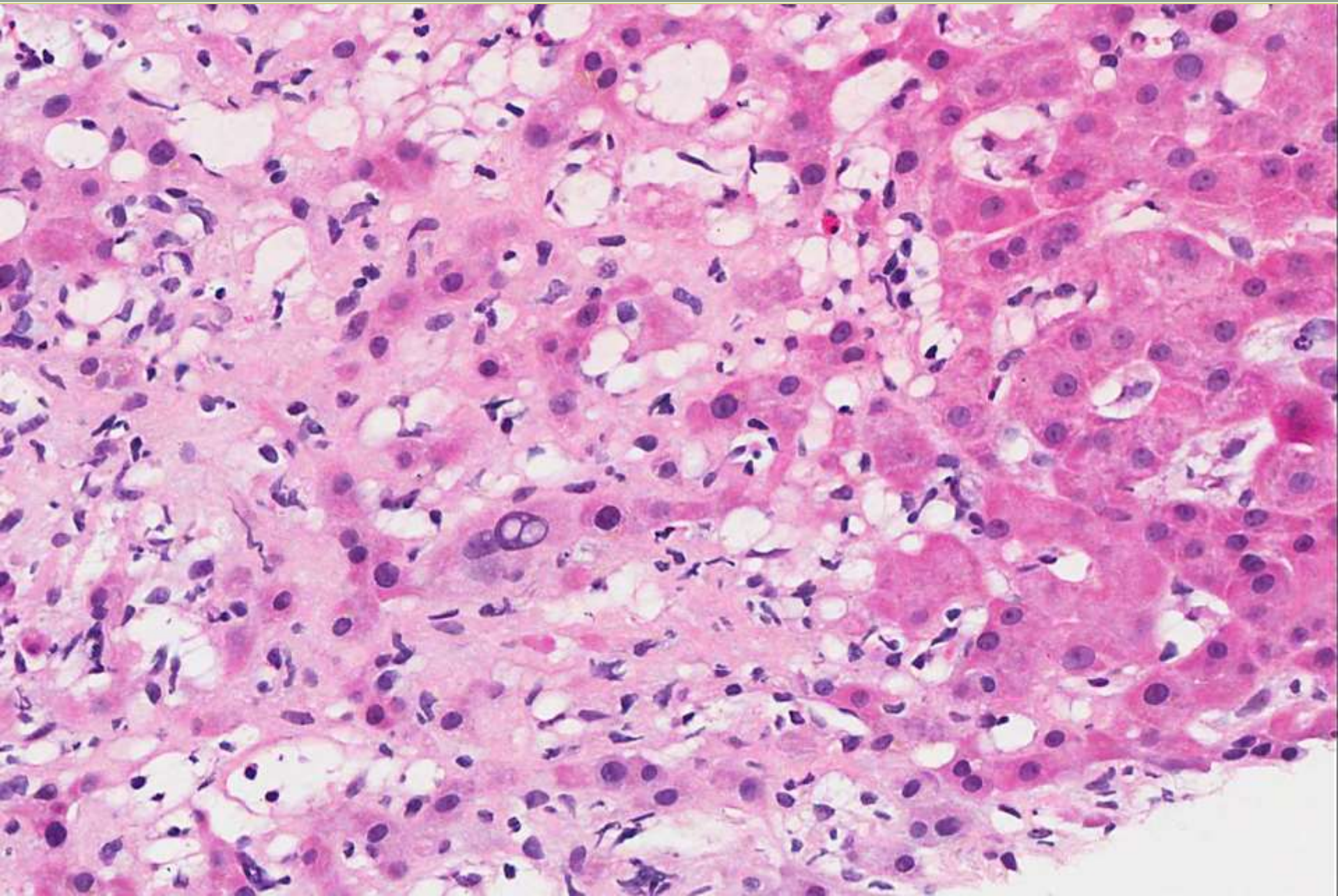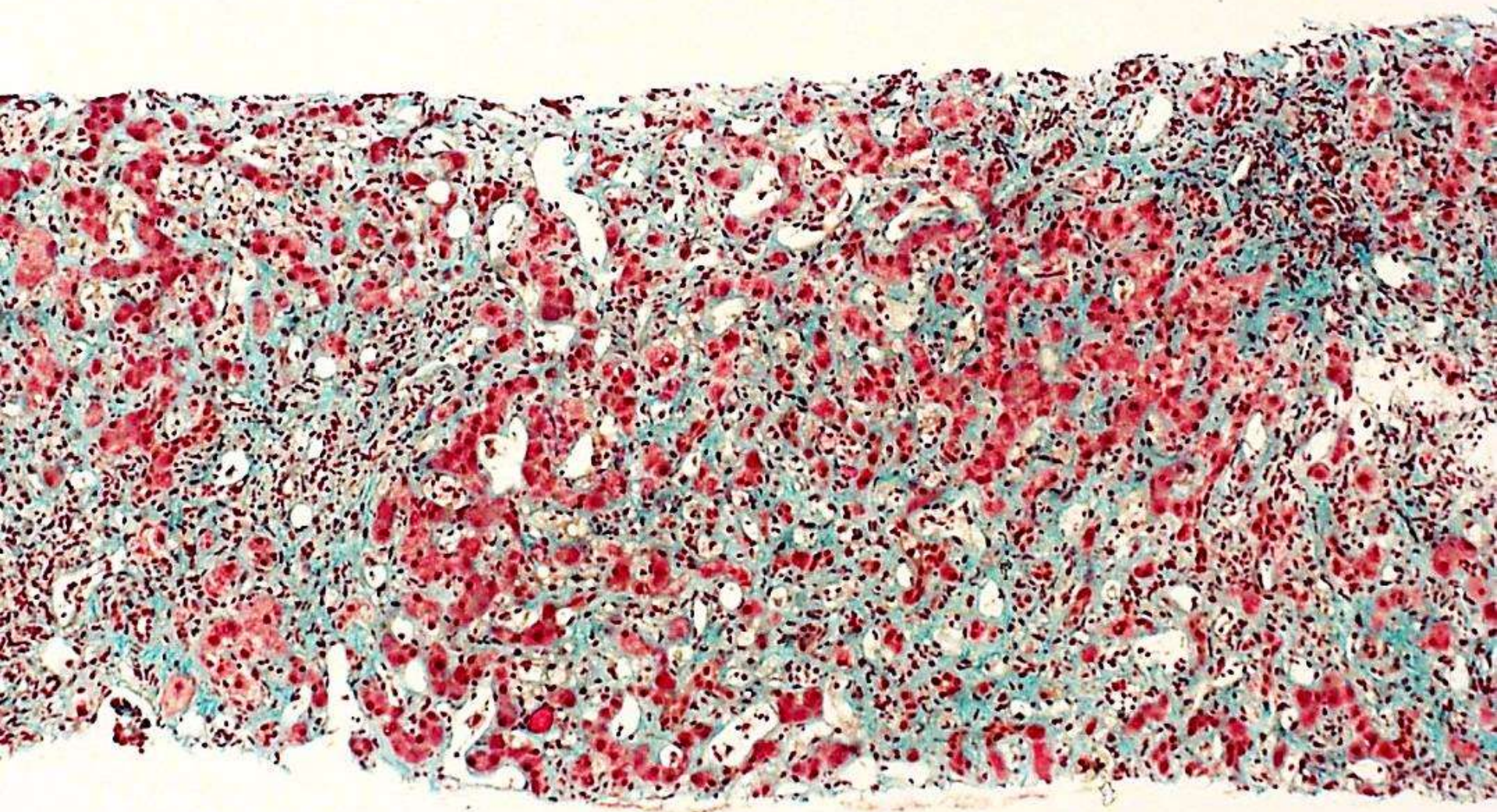
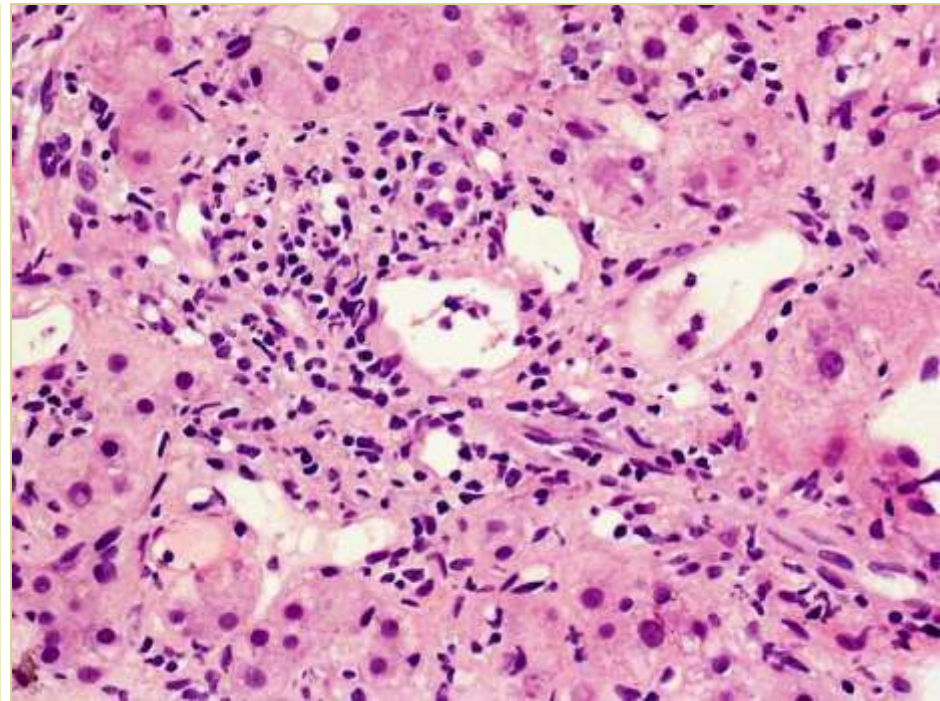
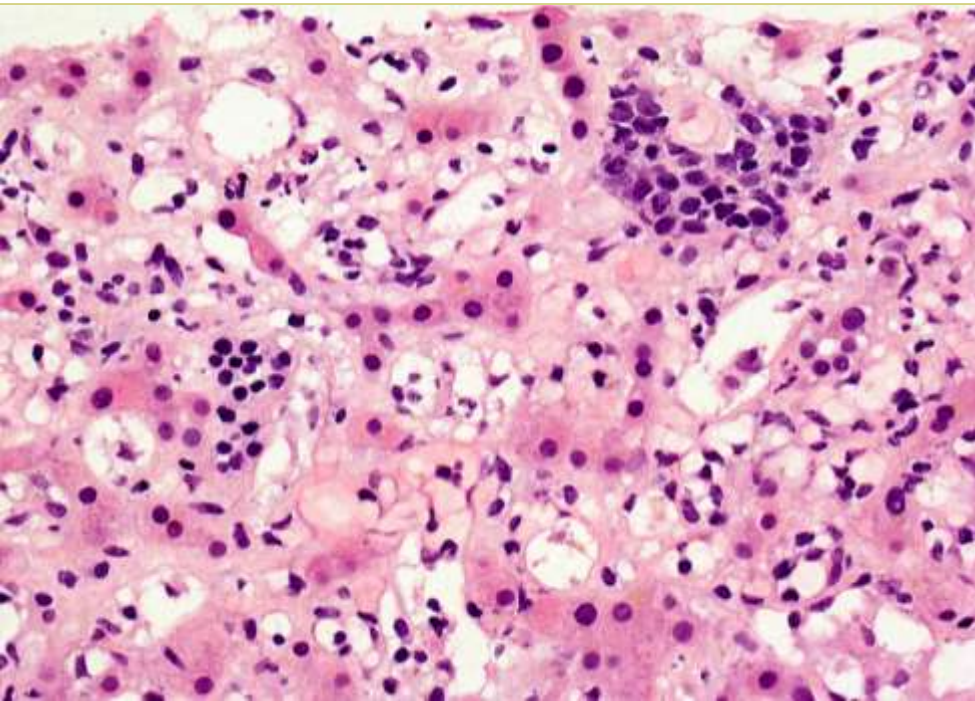
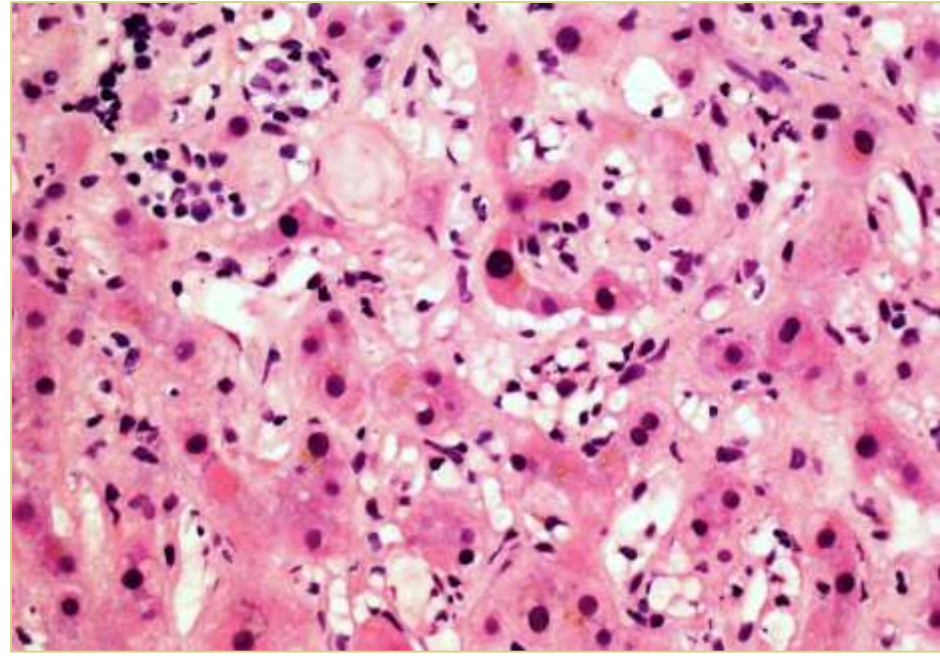
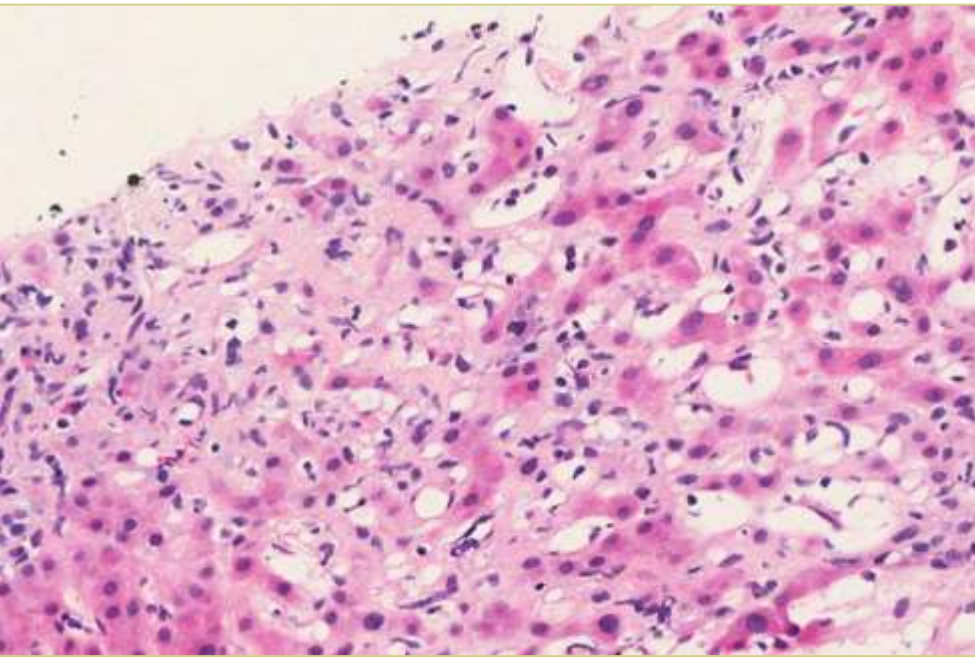


Core biopsy of liver



Masson trichrome



Case 6 A Young Woman with Perisinusoidal Fibrosis

- Describe the histological findings.
- What further tests would you order?
- What is your provisional diagnosis?